


CASE REPORT

HORSE-TRAUMATIC WOUND

GENERAL INFORMATION

Gelding, Warmblood, 18 years
Injury after collision with car

PREVIOUS TREATMENT

Surgical reconstruction with skin flap. Necrosis of flap after 7 days followed by an antiseptic treatment during 14 days without improvement of the wound condition. Start treatment with  on day 21 after injury.

TREATMENT WITH


WOUND CLEANSING

Saline solution

SECONDARY DRESSING

None

OTHER

No systemic antibiotic treatment. No local antiseptic treatment after treatment start with .

RESULT

TIME TO WOUND CLOSURE

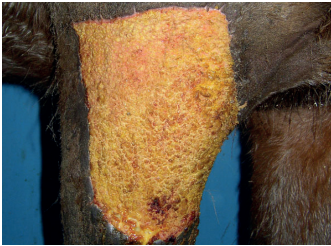28 weeks

TIME TO HAIR GROWTH

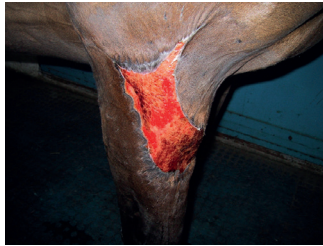16 weeks

OBSERVATIONS

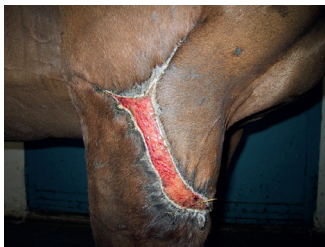- No flies on the wound (despite lack of secondary dressing).
- Hair grew back with same pigmentation.



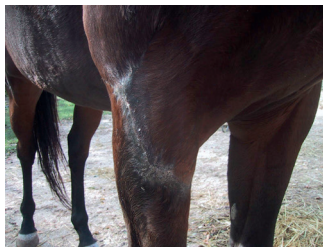
DAY 0 Start treatment with 



DAY 62



DAY 117



DAY 119

CONCLUSION VETERINARY

Dr. Fiorella Carnevali
Italy

“The 23x13cm wound showed no improvement after 20-day antiseptic treatment.”

“After application of one a fast formation of granulation tissue could be observed. The resulting scar is small and of good functional quality.”

“The wound healed without complication despite lack of secondary dressing or additional medication.”

CONTACTS

PRODUCER

Phytoceuticals AG
CH-8008 Zurich

ADDITIONAL INFO

www.onewound.com
Tel. +41 58 800 58 58

