

CASE REPORT

VASCULAR ULCER, ARTERIAL

GENERAL INFORMATION

76-year old female patient with an arterial ulcer, leg lateral malleolus

PREVIOUS TREATMENT

Healing by secondary intention with hydrocolloid for 30 days without improvement of the wound condition. Start treatment with ① 30 days following incidence.

TREATMENT WITH ①

WOUND CLEANSING

Saline solution

SECONDARY DRESSING

Non-woven gauze

OTHER

Due to strong pain the fibrin layer was not actively removed.

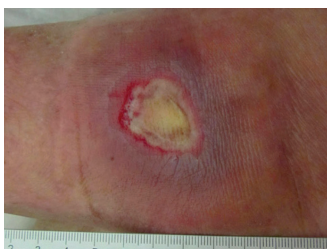RESULT

TIME TO WOUND CLOSURE

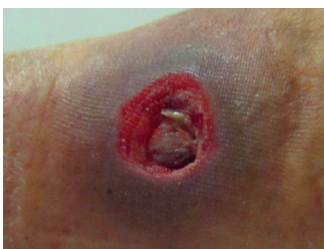82 days

OBSERVATIONS

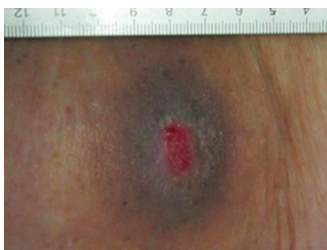
- ① supports autolytic debridement.
- Patient was able to perform the dressing change at home herself.



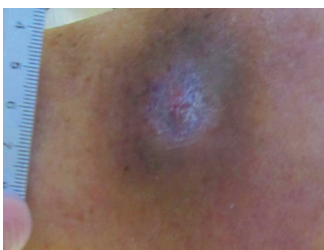
DAY 1 Start treatment with ①



DAY 13



DAY 54



DAY 82

CONCLUSION MEDICAL DOCTOR

Dr. F. Castrignano, MD
Italy

“1” supports autolytic debridement which is especially helpful for patients that are very pain-sensitive. A vast solution of the fibrinous core was observable within the first 10 days. Thereafter, a strong induction of granulation tissue growth was visible which resulted in complete wound closure without complications.”

“It was very helpful that the patient was able to perform the dressing change between the visits at my practice herself.”

CONTACTS

PRODUCER

Phytoceuticals AG
CH-8134 Adliswil

FURTHER INFORMATION

www.wound.ch
Tel. +41 58 800 58 58

