


# CASE REPORT

## DOG-TRAUMATIC WOUND

### GENERAL INFORMATION

Crossbreed, male, 14 years  
Injury caused by barbed wire

### PREVIOUS TREATMENT

Surgical reconstruction.  
Suture dehiscence on day 4, skin did not take. Antiseptic and antibiotic treatment. No granulation tissue visible and beginning necrosis. Treatment start with  on day 7.

### TREATMENT WITH

#### WOUND CLEANSING

Saline solution

#### SECONDARY DRESSING

None

#### OTHER

Stop antibiotic and antiseptic treatment on day 7 after injury.

### RESULT

#### TIME TO WOUND CLOSURE

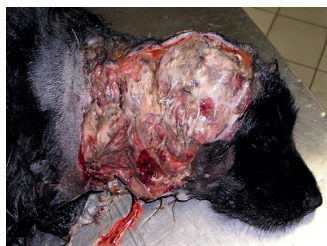Appr. 10 months

#### TIME TO HAIR GROWTH

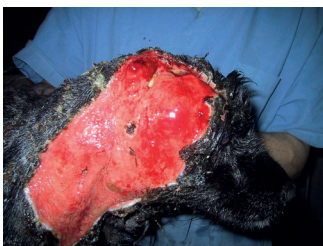3 weeks

#### OBSERVATIONS

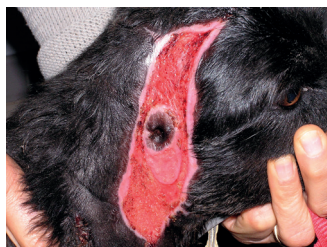No infection (despite the absence of systemic antibiotic treatment and absence of a secondary dressing).



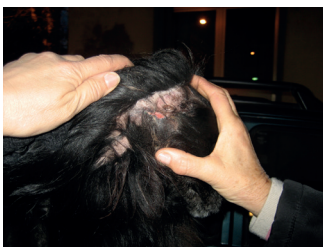DAY 4



DAY 13



DAY 45



DAY 300

### CONCLUSION VETERINARY

Dr. Fiorella Carnevali  
Italy

*"The fact that the previous treatment showed no improvement is a clear indication for the dog's bad general health status."*

*"I was therefore surprised that the wound condition improved quickly after starting treatment with one. I was particularly impressed by the fact that the dog did not develop an infection since the systemic antibiotic treatment was stopped at day 7."*

*"one seems to create a wound environment which is beneficial for the body to activate its capacity to heal the wound."*

## CONTACTS

### PRODUCER

Phytoceuticals AG  
CH-8008 Zurich

### ADDITIONAL INFO

[www.onewound.com](http://www.onewound.com)  
Tel. +41 58 800 58 58

