


CASE REPORT

HORSE-TRAUMATIC WOUND

GENERAL INFORMATION

Mare, Warmblood, 11 years
Abscess growth after injury

PREVIOUS TREATMENT

Abscess exploration followed by antibiotic and antiinflammatory treatment. Wound presented necrotic tissue and pus. Treatment start with  1 day after abscess exploration.

TREATMENT WITH


WOUND CLEANSING

Saline solution

SECONDARY DRESSING

None.

OTHER

Stop antibiotic and antiseptic therapy during treatment with .

RESULT

TIME TO WOUND CLOSURE

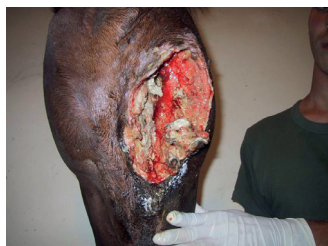7 weeks

TIME TO HAIR GROWTH

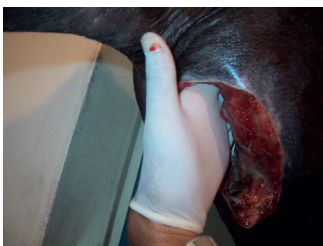2 weeks

OBSERVATIONS

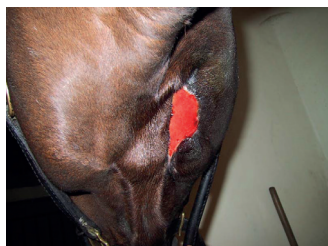Quick induction of granulation tissue formation.



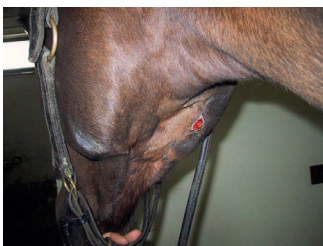
DAY 0 Start treatment with 



DAY 4



DAY 35



DAY 70

CONCLUSION VETERINARY

Dr. Fiorella Carnevali
Italy

"Treatment with one led to a quick induction of granulation tissue formation which resulted in a short time to wound closure."

"I was impressed by the speed of the functional recovery of eating and drinking. The salivar fistula healed without the need for surgical intervention."

CONTACTS

PRODUCER

Phytoceuticals AG
CH-8008 Zurich

ADDITIONAL INFO

www.onewound.com
Tel. +41 58 800 58 58

