


CASE REPORT

HORSE-TRAUMATIC WOUND

GENERAL INFORMATION

Gelding, Warmblood, 14 years
Injury during transport

PREVIOUS TREATMENT

Beginning formation of "proud flesh" and worsening wound condition with exposed bone after 7-day antiseptic and antibiotic treatment. Start treatment with  on day 8 after injury.

TREATMENT WITH

WOUND CLEANSING

Saline solution

SECONDARY DRESSING

Semi-occlusive pressure bandage

OTHER

Antibiotic treatment was stopped on day 14 and antiseptic treatment was stopped on day 8 after injury.

RESULT

TIME TO WOUND CLOSURE

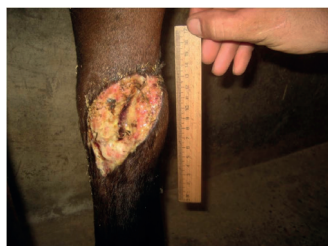15 weeks

TIME TO HAIR GROWTH

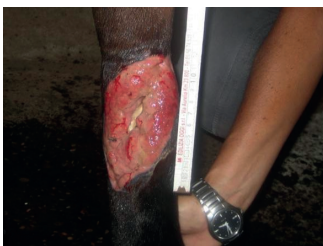4 weeks

OBSERVATIONS

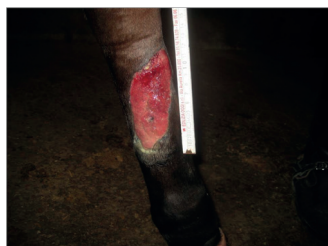Quick regression of exuberant granulation tissue.



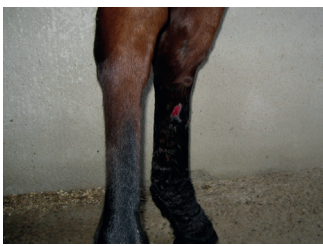DAY 0 Start treatment with 



DAY 14



DAY 28



DAY 90

CONCLUSION VETERINARY

Dr. Fiorella Carnevali
Italy

"The wound immediately started to form exuberant granulation tissue. The combination of one with a semi-occlusive pressure bandage enabled perfect control of the exuberant granulation tissue. The wound then healed without complications."

"one has an antimicrobial effect and promotes wound healing in an ideal way which enables the treatment of such wounds without the need for further antiseptic treatment."

CONTACTS

PRODUCER

Phytoceuticals AG
CH-8008 Zurich

ADDITIONAL INFO

www.onewound.com
Tel. +41 58 800 58 58

